



Successful Treatment of Acute Leg Ischemia with a Hybrid Approach

Akut Bacak İskemisinin Hibrit Yaklaşımla Başarılı Tedavisi

Ahmet Güner¹, Anıl Avcı¹, Mehmet Aksüt²

¹ University of Health Sciences, Kartal Koşuyolu High Specialization Health Application and Research Center, Clinic of Cardiology, İstanbul, Turkey

² University of Health Sciences, Kartal Koşuyolu High Specialization Health Application and Research Center, Clinic of Cardiovascular Surgery, İstanbul, Turkey

A 60-year-old male patient was admitted to our emergency department with left lower extremity pain. He underwent bilateral femoropopliteal bypass 3 years ago and had smoking habit and no other disease, except for Type-II diabetes mellitus. He was evaluated using bedside Doppler ultrasonography, and no flow was observed in the left popliteal artery and its distal branches. Therefore, the patient was transferred to the catheter laboratory and was found to have 100% occlusion of the left femoropopliteal graft, femoral artery, and its distal branches, and an intense thrombus in the contralateral peripheral angiography through the right femoral artery. Revascularization was not achieved with the percutaneous approach and thrombolytic therapy. The patient was followed up daily by the orthopedic team and prepared for left lower extremity amputation. On the 6th day of follow-up, acute-onset pain developed in the right lower limb; palpation showed loss of the popliteal artery and distal pulses. The thrombus developed secondary to the arterial sheath in the right femoral artery in the atherosclerotic zone, and consequently, it was considered to be thromboembolism in the right femoropopliteal graft and its distal branches. Doppler ultrasonography showed no flow in the anterior and posterior tibial arteries. Embolectomy was performed by the cardiovascular surgery team. The right femoropopliteal artery graft was incised proximally. However, inflow was not observed in the graft incision area. Successful embolectomy was not performed from the proximal anastomosis region of the graft with the Fogarty catheter. The patient was taken to the catheter laboratory for right peripheral angiography. Retrograde angiography performed through the graft incision site revealed that the right iliac artery had a total occlusion. Next, a 0.014-inch guiding wire (Choice 300 cm, Boston Scientific, USA) was pushed forward into the abdominal aorta through a retrograde approach from the graft incision site. After determining that the guide wire was in the arterial lumen by the catheter injection, successive dilatations were performed using a 4.0 × 150-mm balloon (Coyote, Boston Scientific, USA) (Figure 1A). It was seen that the inflow of the graft improved after angioplasty. Thrombectomy was performed to the distal of the graft by passing a Fogarty catheter (Edwards Lifesciences Corp., CA, USA) under fluoroscopy (Figure 1B,C). After thrombectomy, the graft incision area was repaired by suturing. During the follow-up of the patient, the symptoms of the right lower limb were regressed, the legs returned to normal from the cyanotic color, and leg temperature increased by palpation (Figure 1D). Control Doppler ultrasonography also showed triphasic flow in arterial traces.

Acute limb ischemia is a cardiovascular disorder that may begin with sudden arterial occlusion, have catastrophic consequences, and result in limb amputation in 10%-15% patients⁽¹⁾. The prevalence of peripheral arterial disease, which usually develops on the basis of atherosclerosis increases with age⁽²⁾. Hybrid revascularization, i.e., endovascular treatment and open surgery in combination, can be used particularly for reaching the occluded arterial segment in patients not having an alternative intervention site^(3,4). In this case, we successfully treated the native artery and graft thrombo-occlusion, which caused acute leg ischemia, by revascularizing with the hybrid approach.

Correspondence

Ahmet Güner

E-mail: ahmetguner488@gmail.com

Submitted: 10.08.2017

Accepted: 11.10.2017

© Copyright 2018 by Koşuyolu Heart Journal.
Available on-line at
www.kosuyoluheartjournal.com

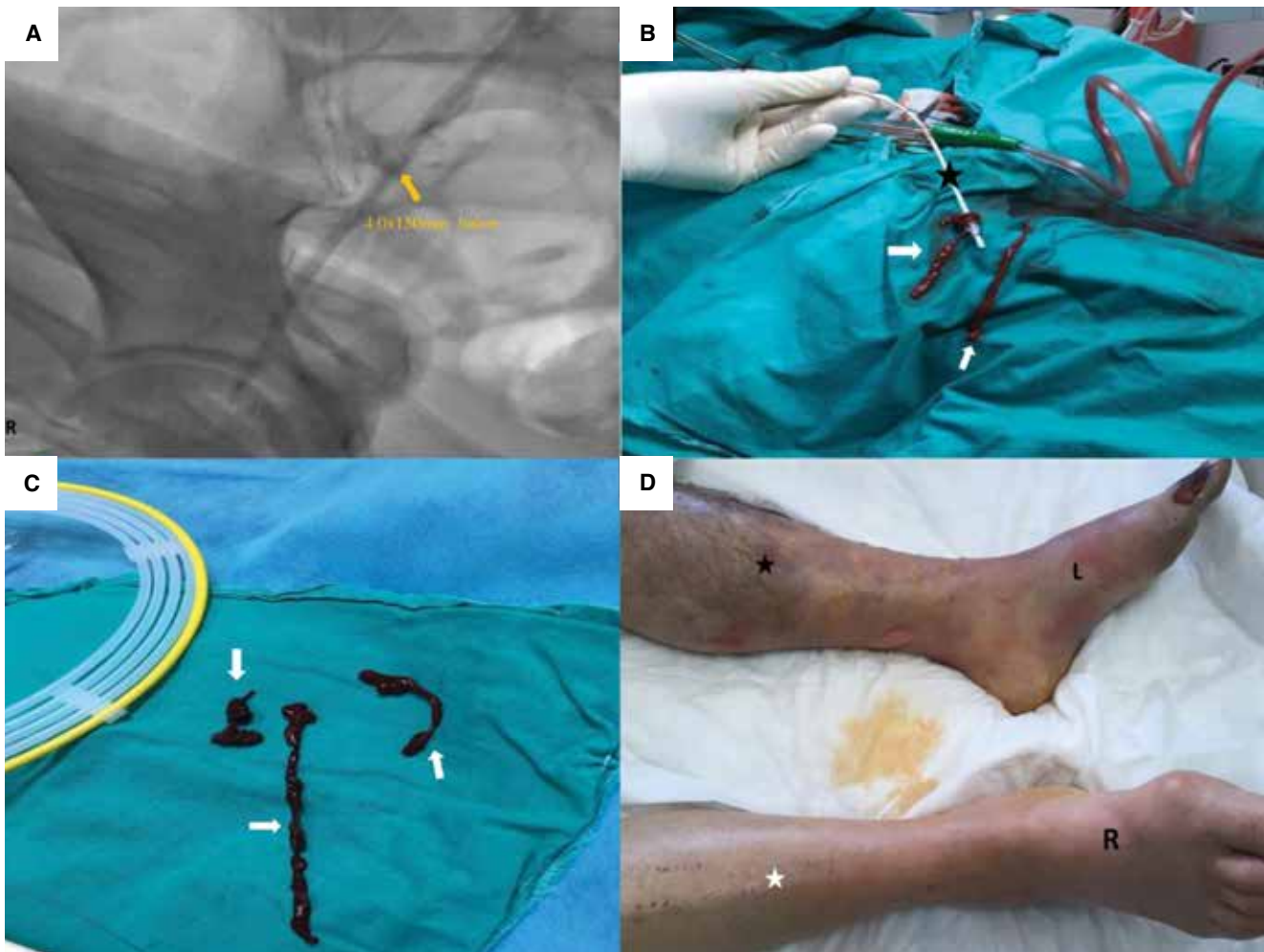


Figure 1. (A) A 4.0 × 150-mm peripheral balloon (yellow arrowhead) can be seen extending from the right external iliac artery to the main iliac artery. (B) A Fogarty catheter (black star) and removed thromboses can be noted (white arrow head). (C) Total fresh thrombus removed with the Fogarty catheter (white arrowheads). (D) The patient's leg on which the successful embolectomy was performed (white star) and the leg prepared for amputation (black star).

REFERENCES

1. Acar RD, Sahin M, Kirma C. One of the most urgent vascular circumstances: Acute limb ischemia. *SAGE Open Med* 2013;1:20.
2. Balkanay OO, Ömeroğlu SN. Approach to peripheral arterial disease in the elderly. *Türk Kardiyol Dern Ars* 2017;45(Suppl 5):s96-101.
3. Grandjean A, Iglesias K, Dubuis C, Déglise S, Corpataux JM, Saucy F. Surgical and endovascular hybrid approach in peripheral arterial disease of the lower limbs. *Vasa* 2016;45:417-22.
4. Joh JH, Joo SH, Park HC. Simultaneous hybrid revascularization for symptomatic lower extremity arterial occlusive disease. *Exp Ther Med* 2014;7:804-10.