

# Preventing Mechanical Complications of Median Sternotomy Using Venous Cannula Line



## Venöz Kanül Hattı Kullanılarak Medyan Sternotominin Mekanik Komplikasyonlarının Engellenmesi

Serkan Ketenciler, Kamil Boyacıoğlu, İknur Akdemir, Nihan Kayalar

Istanbul Okmeydanı Training and Research Hospital, Clinic of Cardiovascular Surgery, İstanbul, Turkey

Mechanical complications of median sternotomy, such as sternal dehiscence, fracture, and mediastinitis, may cause significant morbidity and mortality in patients who undergo cardiac surgery. These complications can lead to prolonged hospitalization and sometimes require surgical sternum revision<sup>(1)</sup>. In high-risk patients, such as those with chronic obstructive lung disease, morbid obesity (BMI > 30), chronic renal failure, diabetes mellitus, chronic steroid use, reoperative surgery, older age, off midline sternotomy, and osteoporosis, complications of sternotomy may occur more frequently. Although stainless steel wire closure remains the standard technique for stabilizing the sternum after sternotomy, many different and novel techniques or devices and corsets have been utilized to reinforce sternum stabilization<sup>(1-6)</sup>. All these techniques are used at the end of the surgery or during the postoperative period. However, our simple method aims to protect the sternum during the surgery, thereby reducing the rate of complications.

### Technique

After median sternotomy, the sternal bone is first examined to assess whether sternotomy is in the midline or off the midline. The structure of the bone is also evaluated for the presence of fragility or inadvertent fractures. Then, a piece of large venous cannula line of sufficient length is divided into two equal pieces. Each piece is longitudinally cut to form two elastic and soft covers to fit the free sternal edges (Figure 1A,B). Initially, the free edges of the sternum are covered with sterile clothes or gauze, followed by placing the pieces of previously prepared venous cannula line on the clothes (Figure 2). Finally, a sternum retractor is placed to open the mediastinum, and the pieces of venous cannula line remain between the retractor and sternal edges (Figure 3).

### Discussion

Postoperative sternal dehiscence with or without mediastinitis is a serious complication of cardiac surgery, which may lead to considerable disability. New tools or corsets are usually aimed at preventing sternal separation after surgery, but they cannot prevent sternal fracture, smash, damage, or costochondral fractures, which may be created by sternal retractor, during the surgery. Using cannula lines, we believe that the pressure on the free edges of the sternum due to the retractor may be equally distributed along the entire edge of the sternum. Thus, when the mediastinum is opened, the separation of the sternum becomes easier and safer, and the rate of occurrence of fractures may be minimized. Moreover, the technique also increases the success rate of sternal reconstruction using stainless steel wires or other new tools because of decreased sternal damage during surgery. This may also decrease the use of newly developed sternal constructing tools, which may in turn decrease the cost. Indeed, one of the main advantages of this technique is the very low cost without the need of extra tools. The venous cannula lines of the cardiopulmonary bypass tube system can be used in all open cardiac surgeries, and an appropriate length of the line can be easily cut out. This line is large, soft, elastic and sufficiently thick to form a protective cushion between the sternum and retractor. It easily molds around the sternal edge due to the initial tubal structure, making it suitable for the sternal edge. We believe that this technique is very simple, cheap, and effective for protecting the sternal bone during cardiac surgery, especially in patients with risk factors for sternal complications, such as old age, osteoporosis, fragile bones, fractures during sternotomy, and removal of sternal wires from previous cardiac surgeries.

### Correspondence

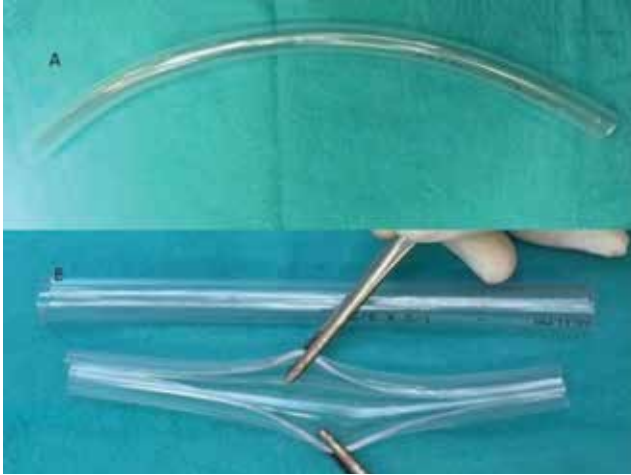
**Kamil Boyacıoğlu**

E-mail: kamilboyacioglu@yahoo.com.tr

Submitted: 23.10.2017

Accepted: 11.12.2017

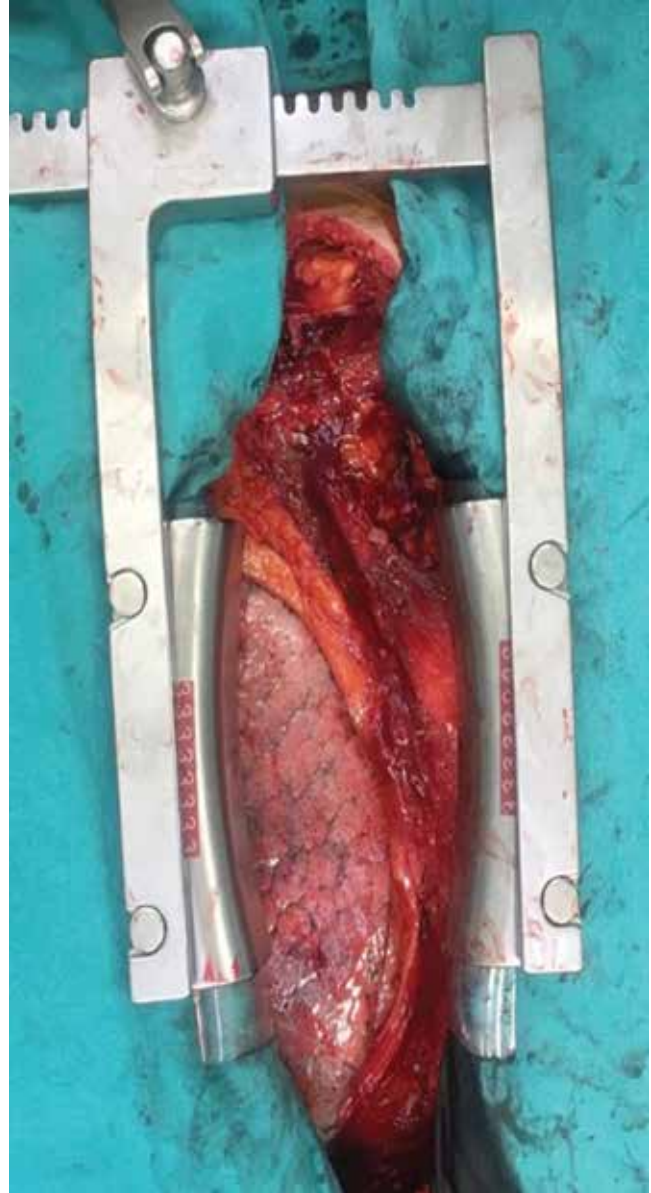
© Copyright 2018 by Koşuyolu Heart Journal.  
Available on-line at  
www.kosuyoluheartjournal.com



**Figure 1** (A) Venous cannula line. (B) Two equal venous cannula lines which are longitudinally cut.



**Figure 2.** Prepared venous cannula lines are placed on the clothes.



**Figure 3.** The venous cannula lines are between the sternum retractor and free edges of the sternum.

## REFERENCES

1. Caimmi PP, Sabbatini M, Kapetanakis EI, Cantone S, Ferraz MV, Cannas M, et al. A randomized trial to assess the contribution of a novel thorax support vest (corset) in preventing mechanical complications of median sternotomy. *Cardiol Ther* 2017;6:41-51.
2. Huh J, Bakaeen F, Chu D, Wall MJ Jr. Transvers sternal plating in secondary sternal reconstruction. *J Thorac Cardiovas Surg* 2008;136:1476-80.
3. Fedak PW, Kieser TM, Maitland AM, Holland M, Kasatkin A, Leblanc P, et al. Adhesive-enhanced sternal closure to improve postoperative functional recovery: a pilot, randomized controlled trial. *Ann Thorac Surg* 2011;92:1444-50.
4. Ashley N, Boustany, Ghareeb P, Lee K. Prospective, randomized, single blinded pilot study of a new FlatWire based sternal closure system. *J Cardiothorac Surg* 2014;9:97.
5. Negri A, Manfredi J, Terrini A, Rodella G, Bisleri G, El Quarra S, et al. Prospective evaluation of a new sternal closure method with thermoreactive clips. *Eur J Cardiothorac Surg* 2002;22:571-5.
6. Motomatsu Y, Imasaka K, Tayama E, Tomita Y. Midterm results of sternal band closure in open heart surgery and risk analysis of sternal band removal. *Artif Organs* 2016;40:153-8.