



# Successful Catheter Cryoablation for Atrial Fibrillation in Patients with Permanent Cardiac Pace-maker Implants

Hacı Murat Güneş, Gamze Babür Güler, Gültekin Günhan Demir, Fethi Kılıçaslan

University of İstanbul Medipol, Faculty of Medicine, Department of Cardiology, İstanbul, Turkey

## ABSTRACT

In daily practice, several methods including electrocardiography, 24-hour Holter ECG monitoring, or event recorders are frequently used for diagnosis and follow-up of patients with atrial fibrillation (AF). Although these tests provide crucial information, they may be insufficient in selected cases. In this case, we utilized intracardiac electrocardiogram recordings for both diagnosis of AF and detection of its recurrence in a patient with a permanent pace-maker who underwent AF ablation because of symptomatic and asymptomatic paroxysmal AF episodes. Because patients with permanent pacemakers are continuously monitored via intracardiac recordings, we believe that it is the most definite method for both diagnosis and monitoring of treatment success.

**Key Words:** Atrial fibrillation ablation; intracardiac recordings

## Kalıcı Kalp Pili İmplantı Olan Atriyal Fibrilasyonlu Hastada Başarılı Kateter Kriyoablasyon

### ÖZET

Günlük pratikte hastalarda atriyal fibrilasyon ataklarının tanı ve takibinde sıklıkla elektrokardiyografi, ritim holter ve olay kaydedici kullanılmaktadır. Bu testler önemli bilgi sağlasa da yetersiz kaldıkları olgular olabilmektedir. Biz olgumuzda daha önce kalıcı kalp pili implante edilmiş, semptomatik ve asemptomatik atriyal fibrilasyon atakları olan hastanın tanısının koyulmasında ve atriyal fibrilasyon ablasyonu sonrası rekürrens takibinde kalp içi kayıtlardan faydalandık. Kalıcı kalp pili olan hastalarda, intrakardiyak kayıtlarla devamlı takip sağladığından, hem tanı koymada hem de tedavi başarısını belirlemede kullanılabilir en kesin yöntem olduğunu düşünüyoruz.

**Anahtar Kelimeler:** Atriyal fibrilasyon ablasyonu; intrakardiyak kayıtlar

## INTRODUCTION

Catheter-based ablation methods are recommended as the first-line treatment for symptomatic patients with atrial fibrillation (AF) or for those having symptoms despite medical treatment<sup>(1)</sup>. Although diagnosis of symptomatic patients with AF is easy, it may be challenging to diagnose AF in asymptomatic patients. Monitoring pharmacological or interventional treatment efficacy requires utilization of several methods including the most commonly used electrocardiogram (ECG) or 24-hour ambulatory ECG monitoring, which may not always provide satisfactory data. Here, we detected symptomatic and asymptomatic AF episodes by examining intracardiac electrocardiograms (IEGM) of a patient with a permanent pace-maker and then performed pulmonary vein isolation using the cryoballoon technique leading to curative success, which was confirmed by the absence of AF recurrence in IEGMs.

## CASE REPORT

A 70-year-old female patient was admitted with complaints of palpitation and shortness of breath. The patient was implanted with a permanent pace-maker for sick sinus syndrome a year ago in our clinic. Although she was receiving amiodarone and metoprolol therapy for rate and rhythm control, she was noted to have symptomatic (consistent with event time) and asymptomatic AF episodes when examined for IEGMS. Echocardiographic examination

## Correspondence

Hacı Murat Güneş

E-mail: dr\_muratgunes@hotmail.com

Submitted: 19.10.2015

Accepted: 04.02.2016

© Copyright 2018 by Koşuyolu Heart Journal.  
Available on-line at  
www.kosuyoluheartjournal.com

revealed normal left ventricle ejection fraction (55%), left atrial enlargement (43 mm), and mild mitral regurgitation. AF ablation using cryoballoon was scheduled. Following trans-septal puncture, all the four pulmonary veins were isolated using a cryoballoon catheter (Arctic front<sup>®</sup>, Medtronic Cryocath LP, Kirkland, Canada). Isolation of pulmonary veins was confirmed during and after ablation using a circular mapping catheter. In addition, programmed atrial stimulation and “burst pacing” maneuvers were performed, and no tachycardia was induced. Her symptoms improved, and her follow-up visits confirmed that IEGMs revealed no AF episode (Figure 1).

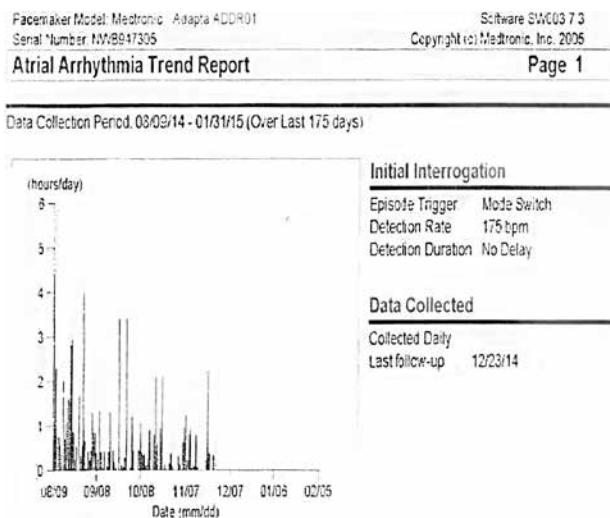
## DISCUSSION

AF is common in patients with pacemakers and is associated with adverse outcomes, particularly in patients with sick sinus syndrome history<sup>(2)</sup>. AF ablation using radiofrequency catheters is a common and effective treatment for such patients<sup>(3)</sup>. Monitoring recurrence after ablation is generally based on the symptoms of the patients in conjunction with 24-hour ambulatory ECG recordings, transtelephonic ECG, or event recorders<sup>(4)</sup>.

Certain forms of pacing modes in patients with pacemakers may not detect very short-lasting AF episodes; however, IEGMs are usually adequate for AF diagnosis and follow-up after ablation. Different from other follow-up methods, more precise records can be obtained using continuous recording. Absence of any AF episode 24-hours after the ablation procedure suggests that IEGM may be an optimal method for the diagnosis and follow-up of patients with pacemakers

## REFERENCES

1. Ichihara N, Miyazaki S, Taniguchi H, Usui E, Takagi T, Iwasawa J, et al. Simple minimal sedation for catheter ablation of atrial fibrillation. *Circ J* 2014;79:346-50.
2. Kristensen L, Nielsen JC, Mortensen PT, Pedersen AK, Andersen HR. Evaluation of pacemaker telemetry as a diagnostic feature for detecting atrial tachyarrhythmias in patients with sick sinus syndrome. *Europace* 2004;6:580-5.
3. Wazni OM, Marrouche NF, Martin DO, Verma A, Bhargava M, Saliba W, et al. Radiofrequency ablation vs antiarrhythmic drugs as firstline treatment of symptomatic atrial fibrillation: a randomized trial. *JAMA* 2005;293:2634-40.
4. Verma A, Minor S, Kılıçaslan F, Patel D, Hao S, Beheery S, et al. Incidence of atrial arrhythmias detected by permanent Pacemakers (PPM) post-pulmonary vein antrum isolation (PVAI) for atrial fibrillation (AF): correlation with symptomatic recurrence. *J Cardiovasc Electrophysiol* 2007;18:601-6.



**Figure 1.** Atrial arrhythmia trend report.